

# Benign Bladder Conditions BAUN Study Day

## “Infections and inflammatory conditions”

Jane Brocksom  
Urology & Continence Nurse Specialist  
St James Hospital. Leeds

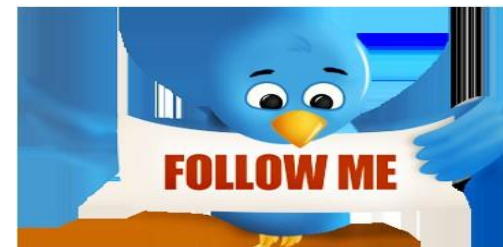[www.baun.co.uk](http://www.baun.co.uk)



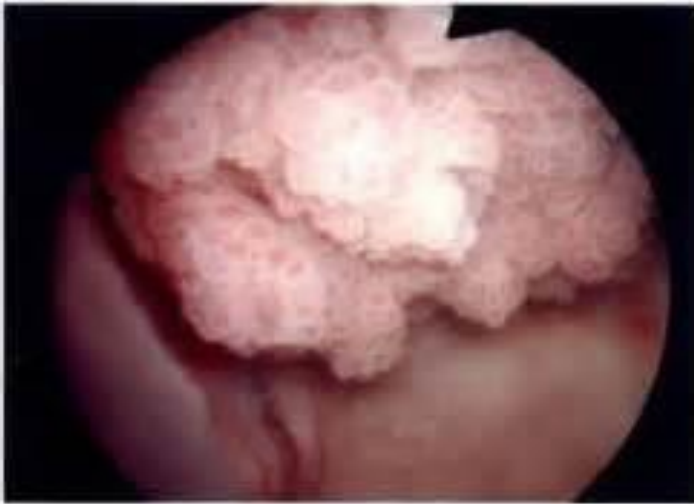@BAUNurses

@HoorayJane

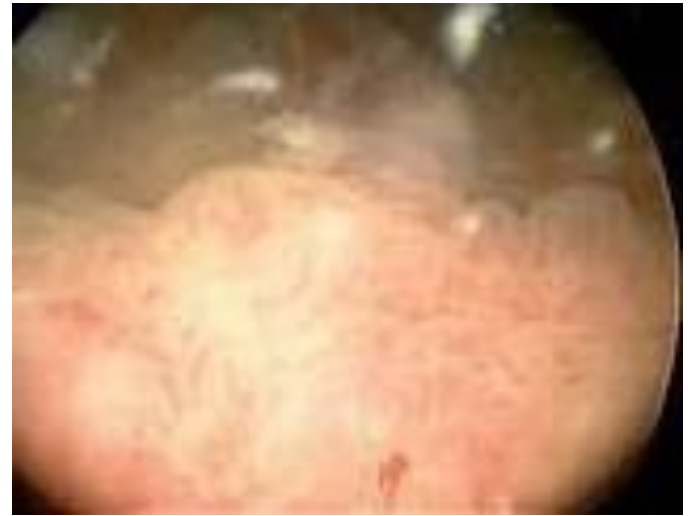#BAUNUrology



A



B



C



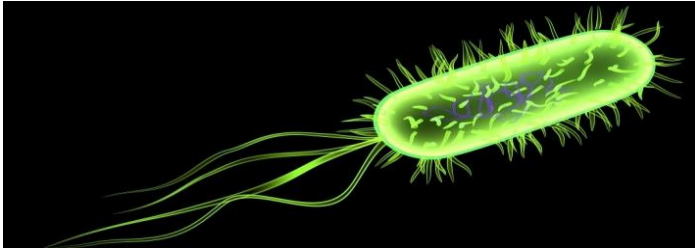
A = Bladder cancer

B = Cystitis

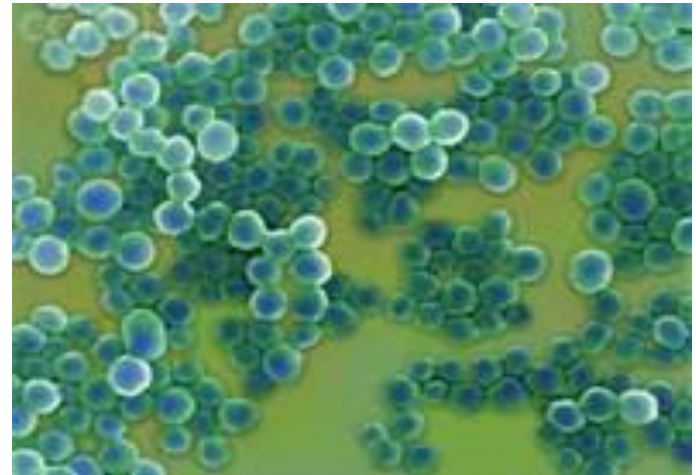
C = Ketamine bladder

# UTI Organisms

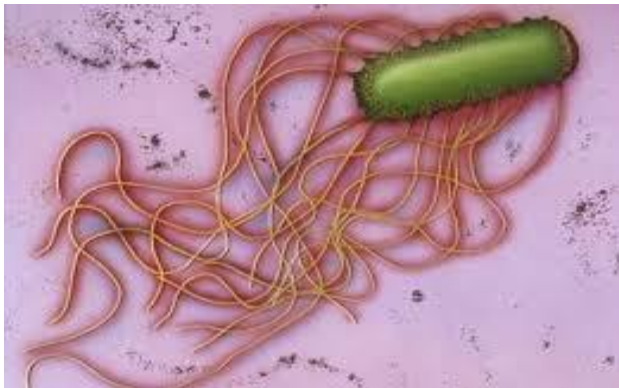
Escherichia coli



Staphylococcus saprophyticus



Proteus mirabilis



Also:      Klebsiella spp.  
             Proteus vulgaris  
             Candida albicans  
             Pseudomonas spp.


# Infections

- Symptomatic

- >100.000 colonising bacteria per ml
- Lifetime risk = 1 in 3 female and 1 in 20 male
  - Bladder mucosa – trauma, stone or tumour
  - Normal voiding – outlet obstruction
  - Periurethral glands/prostatic secretions – catheterisation or instrumentation
- Frequency, urgency, dysuria, small volumes, foul smelling +/- cloudy, suprapubic/loin pain, rigors, pyrexia, nausea/vomiting
- Acute confusion
- Incontinence, Haematuria

# Infections – symptomatic

- Acute cystitis – responds to antibiotic therapy
  - Sexually active female – recur 2 or 3 times per year?
- Management – primary care
- ABx - local policy, microbiologists, GP's, IPS Nurse
  - Uncomplicated
    - » 2 or 3 days antibiotics
  - Complicated
    - » Pregnant, transplant, structural or functional abnormality



# Infections – symptomatic

- Atrophic vaginitis
- GU infections
- Prostate
- Urethritis- catheters/ISC
- Known Urinary tract abnormality
- Foreign body
- Conservative management –

fluids& intake, bladder retraining, hygiene, bowel function, miss matey – chemical irritants, underwear, cranberry juice



# Infections

- **Recurrent symptomatic** – 2 within 6mths/3 within year
  - 20% of women will have recurrent UTI's and more recurrences
  - Prostatitis
  - Urological referral
  - Investigations – upper tracts uss, flexi cystoscopy, U&E's, CT, MRI, voiding cystogram, urodynamics
  - Immune system compromise – HIV
  - Diabetes
- **Male – LUTS** (FROA, PVR, DRE), urinary tract abnormalities, obstruction, anal intercourse, urinary tract surgery
- **Female** – sexual intercourse, contraception, vaginitis, abnormal urinary tract, dysfunctional voiding, pelvic surgery, pelvic examination

# Infections – recurrent symptomatic

- Management

- Longer abx

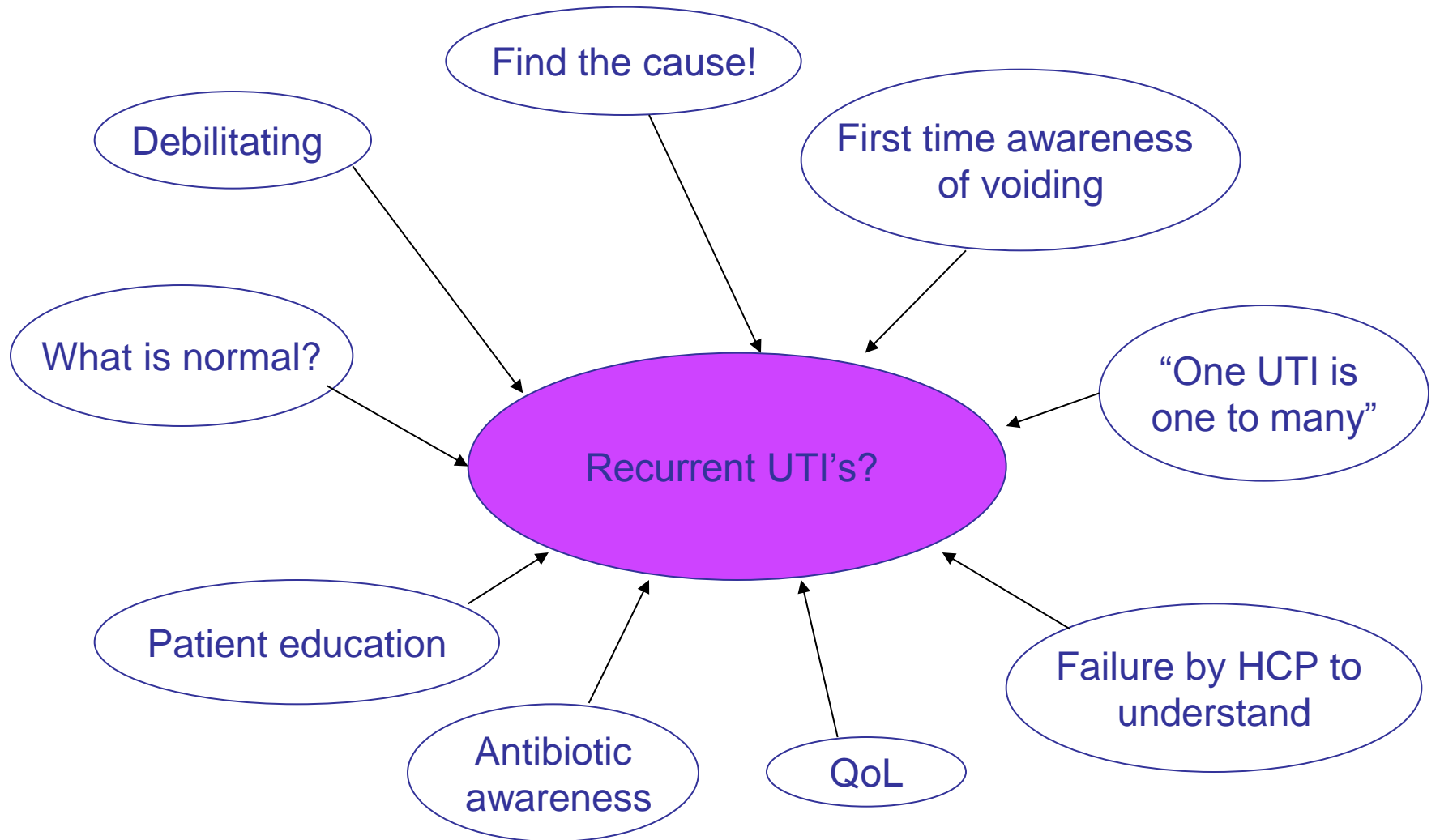
- Find + treat cause

- Prophylaxis

- Lifestyle advice









# Inflammatory



YORKSHIRE



# Asymptomatic to bacteria

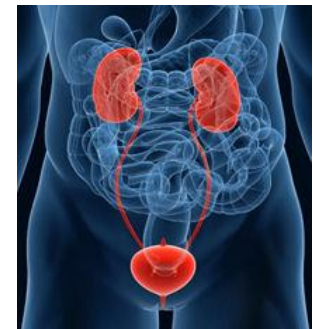- IC, PBS, OAB, SUI, UUI, Neuropathic
- Catheters – indwelling/ISC
- Urethritis
- Post menopausal urogenital atrophy
- Anxiety/stress – MH +/- drugs
- Sexual function
- Prostatitis / Gyrus TURP
- Diabetes
- Conservative management advice

# Sterile Pyuria

- No culture but elevated white cells
  - <2wks since UTI – inadequate or untreated
  - ‘fastidious’ organism – Gonorrhoea / Chlamydia
  - Renal TB
  - Urinary tract stones
  - Urinary tract tumour
  - Polycystic kidneys
  - Interstitial cystitis
  - Prostatitis
  - Appendicitis
- Urinalysis + MC&S for slow growing organism
- STD’s
- TB – 3 early morning urine
- Cystoscopy, USS, U&E’s

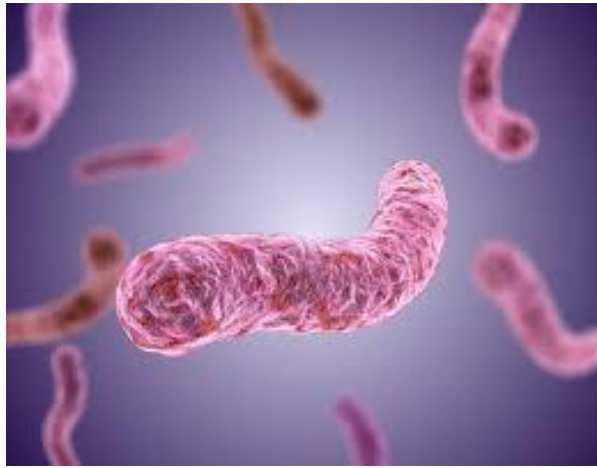
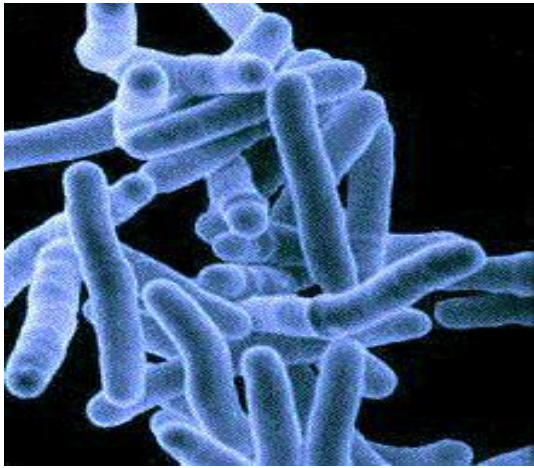
# GUTB –Genitourinary Tuberculosis

- Notifiable disease in the UK – secondary to pulmonary TB up to 5-25yrs after infection, spread via blood stream to GU system
- Bladder = Irritative voiding symptoms of vague, unexplained and long standing origin
- Chronic inflammation gives way to reduced compliance and capacity bladder
- HIV or drug abusers
- Cystoscopy shows superficial inflammation with oedema and granulation. Fibrosis of the ureteric orifice can lead to stricture formation with hydronephrosis, scarification or reflux. In severe cases entire bladder wall, where deep layers of muscle are eventually replaced by fibrous tissue, thus producing a thick fibrous bladder.
- 3-5 early morning urine for culture



# Mycobacterium Tuberculosis

- Cystoscopy – radiological imaging MRI/CT
- Treatment – 6mths antibiotic therapy (adherence) uncomplicated
- Complicated – recurrence or immunosuppressed – 12mths
- Surgically – Nephrectomy for non functioning kidney, reconstructive surgery for strictures, augmentation cystoplasty for bladder




# Radiotherapy bladder

- Radiation cystitis – acute, oedema and haematuria – self limiting and resolves
- Irritative - Urgency, frequency, dysuria, nocturia, haematuria
- Chronic - Small, poor functioning fibrotic bladder, incontinence, urethral strictures
- Changes also seen in patients receiving BCG therapy for superficial bladder cancer

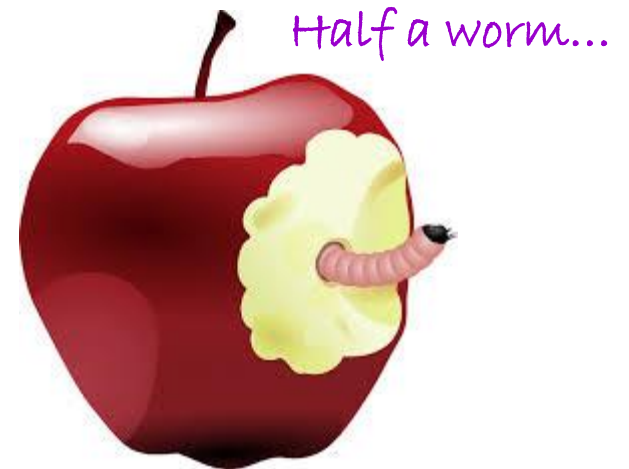# Trematodes

# Nematodes

# Cestodes



What's worse than finding a worm  
in your apple?

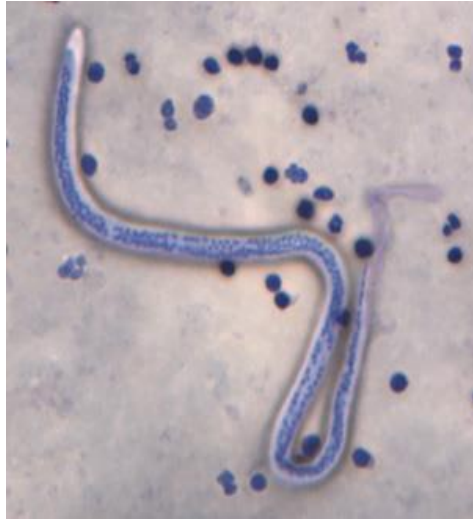
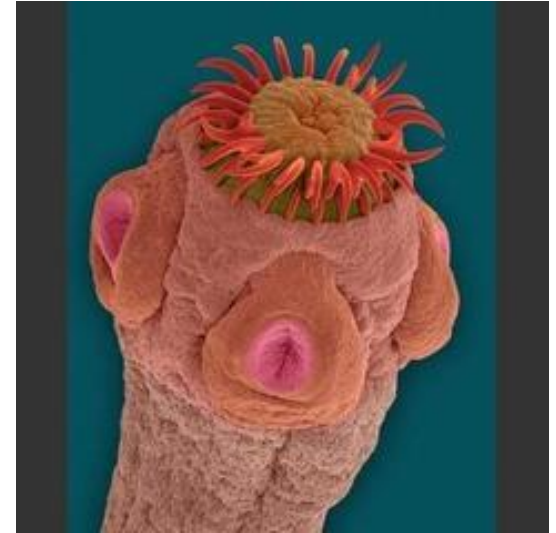
Half a worm...

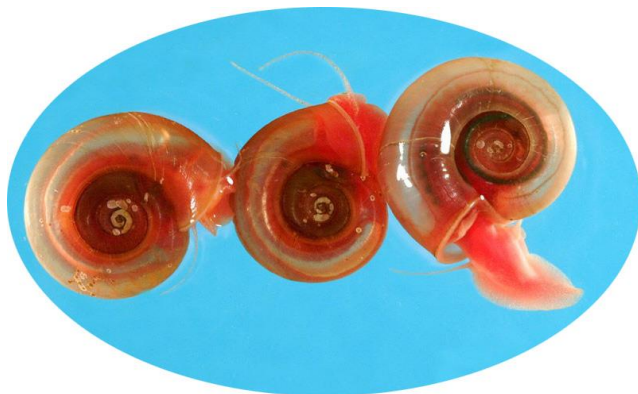


# Parasitic Infections

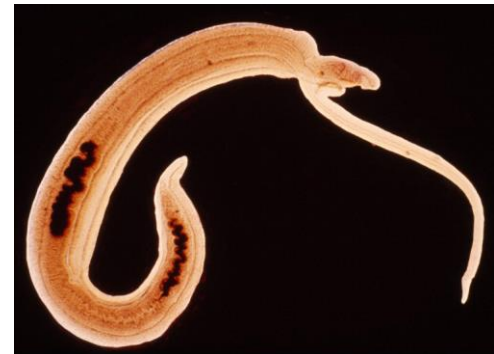Hydatid  
Cestode/tapeworm



Filariasis  
Nematode/Roundworm



Schistosomiasis –  
Trematode/flatworm

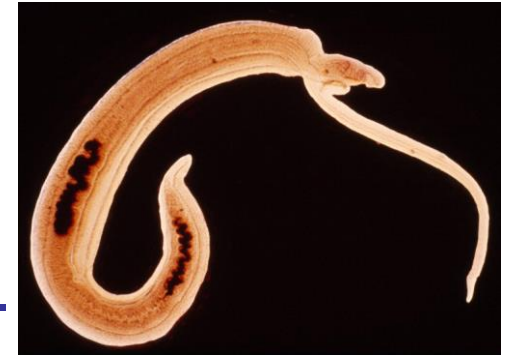

# Parasitic infections

- African, Asia and South American – infectious tropical disease infecting native people/migrants/travellers
- 2<sup>nd</sup> most devastating disease after malaria – in terms of social, economic and public health impact, extreme poverty, sanitary conditions. Endemic 249million in 2012 (WHO)
- First recognised by Egyptian pharaohs
- **Schistosomiasis (Bilharzia – Theodor Bilharz, German pathologist, 1851)**
  - Freshwater snail is intermediate host
  - Human acts as definitive host
  - Infect humans whilst swimming/wading/drinking/washing food or hands
  - Within days rash/itchy skin, few months till fever, muscle aches and haematuria or bloody diarrhoea (8wks to diagnosis)
  - Penetrate the skin, penetrate capillaries and reach bladder, millions of eggs infest urine embed in wall of bladder and die!
  - Eggs contaminate environment, half eggs excreted

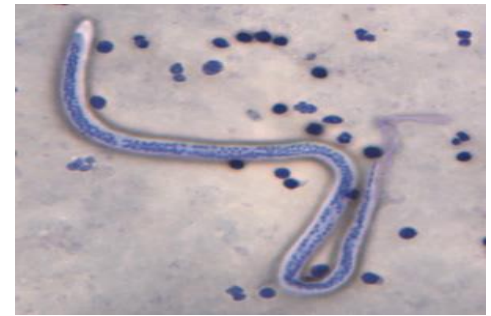
- 1. Schisto.....!

- Produce masses known as bilharzioma....
- Haematuria – oedematous bladder wall
- Fibrotic bladder – calcified bladder wall
- CT
- Cystoscopy + biopsy – SCC later complication
- Rarely involves renal system only 2<sup>nd</sup> to obstruction of distal ureter
- Prostate and urethra involved – forming fistulas
- Treatment with Praziquantel – not licensed in UK to give to humans, go to vets..... (named patient basis)

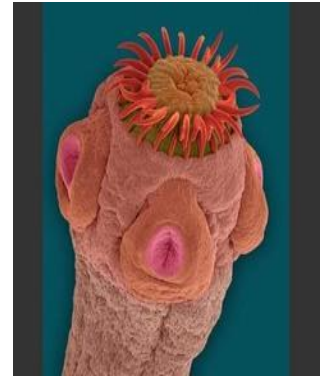

- 2. Filariasis

- Neglected tropical disease –
- 120 million currently infected (WHO) - lymphatic Filariasis.
- Mass annual drug administration single dose of 2 drugs - albendazole + ivermectin or diethylcarbamazine.....
- Threadworms obstruct lymphatic system
- Lymphatic fluid enter bladder – chyle in urine (Chyluria) = Milky white urine, irregular and intermittent
- Elephantitis – 50% of men have genital disfigurement with hydrocele (female breast involvement)
- Social stigma from lymphoedema – increased poverty, isolation and medical expense
- Bacterial infection of skin, mosquito nets, hygiene, skin care, exercise and elevation of affected body parts!



# Hydatid disease



- 1 million living with the disease – WHO aims for effective disease strategy by 2018
- Ingested parasite eggs – food, water or soil – caught from animals (dogs) – zoonotic disease
- Dog owners good hygiene, wash hands after handling, scoop poo!, Praziquantel wormer, wash salads, veg, fruit, dispose of sheep carcasses correctly
- Many years until Hydatid cyst grows to size triggering clinical signs – abdo pain, weight loss, vague pain, low grade pyrexia
- Liver 60%, Lungs 15%, Bladder 2-4% – obstructed voiding, urgency, frequency, dysuria
- Inert unless disrupted – anaphylactic reaction
- Surgery or P.A.I.R (puncture, aspiration, injection, re-aspiration)



Ketamine Bladder - Bristol bladder 2008

Veterinary anaesthetic, legit neuropathic/palliative

Battlefield anaesthetic – short action, muscle paralysis

Date rape drug – disassociation amnesia effect –'K'Hole



*Investigations:*

Cystoscopy - 50ml max

Renal function

Urine C&S

USS renal & Abdo

CT urogram

UDS

*Presenting symptoms:*

UTI like OAB,PBS, IC + ulcerative cystitis

Suprapubic pain

Frank haematuria

Dysuria, urgency, frequency, nocturia, incontinence

*Treatment options:*

MDT - Drug agencies, GP, Pain team, Urologist, Psychiatry, UNS

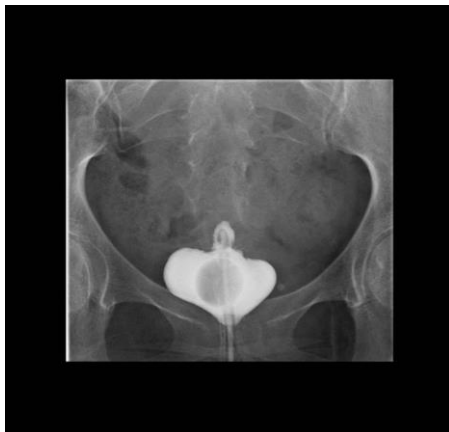Anticholinergics

Intravesical instillations – Cystistat or Pentosan/Elmiron

(Amitriptyline, Steroids, analgesia)

STOP taking Ketamine.....

Bladder augmentation, urinary diversion +/- cystectomy



Be suspicious in young persons with severe LUTS



The early bird can have the  
stupid worm because  
mornings and worms  
suck.



your  cards  
someecards.com

Thank You!